


PATIENT

Anzo Alumbaugh

SPECIES

Feline

BREED

Bengal

SEX

Male Intact

AGE

23 weeks

WEIGHT

5.68lbs; 2.6kgs

INTERPRETED BY

 Maggie Machen Lamy,
 DVM, DACVIM
 (Cardiology)

IMAGING PERFORMED BY

 Loetitia St-Jacques,
 LVT/RVT

HOSPITAL NAME

 VCA Feline Animal
 Hospital

REFERRING VET

Dr. Fleming

INVOICE

21845

DATE

11/2/21

PRESENTING CLINICAL SIGNS

History: General lethargy noted. Neurological episode - 2x recurrent. Appears disorientated, salivating, and unable to move. Resolved after 10 hours.

ELECTROCARDIOGRAPHIC FINDINGS *Note: Single lead ECGs are evaluated as a rhythm strip. Morphology/MEA cannot be definitively commented on.

A single lead ECG is available; 25mm/s, 20mm/mV. The average heart rate is 160bpm with a largely regular rhythm. The rhythm is sinus in origin, with a p for every QRS complex and vice versa. The P and QRS morphologies are positive. No ectopic beats, pauses or other dysrhythmias observed.

ECG diagnosis: Normal sinus rhythm.

ECHOCARDIOGRAM FINDINGS

2D, m-mode, color flow and doppler imaging is available. The left ventricular wall is normal in dimension. There is a diffusely hyperechoic endocardium consistent with mild fibrosis. The papillary muscles are normal in size and hyperechoic. The endocardium appears normal. The left atrium is normal in size. The right atrium is normal in size. The right ventricle appears normal. The mitral valve is normal in structure and mobility. Normal flow through both the RVOT and LVOT. Trace TR. Normal velocity. No AI or PI. No pleural or pericardial effusion seen. No obvious cardiac tumors.

CARDIAC CHART

| FELINE CARDIAC PARAMETERS | BODY WEIGHT (kg) | HR (BPM) | IVSd (cm) <small>(Moise, Pipers)</small> | LVIDd (cm) <small>(Moise, Pipers)</small> | LVWd (cm) <small>(Moise, Pipers)</small> | FS (%) | EF (%) |
|---------------------------|--------------------------------|---|--|--|---|-------------------------------|--------|
| NORMAL PARAMETER | ----- | 150-240 | 0.35-0.55 | <2 (mean 1.5) | 3.5-0.55 | 35-67 | 80-100 |
| PATIENT | 2.6 | NM | 0.45 | 1.4 | 0.42 | 55 | 89 |
| FELINE CARDIAC PARAMETERS | LA/AO <small>(Boon)</small> | LA/AO HEART BASE (Swe) <small>(Abbott)</small> | LA 2D short axis Base view (cm) <small>(Abbott)</small> | LVOT VEL <small>(m/s)</small> | RVOT VEL <small>(m/s)</small> | E max <small>(m/s)</small> | |
| NORMAL | <1.5 | <1.3 | <1.2 | <1.6 | <1.3 | <0.9 | |
| PATIENT | NM | 1.2 | 1.18 | 1.3 | 1.2 | NM | |

*Note: All measurements based upon multi-modal images and methods. An average value is reported.

Adapted from June Boon, Veterinary Echocardiography, 1998

Abbott J & MacLean H JVIM 2006;20: 111-119, Moise et al. Am J Vet Res 47:1476, 1986. Pipers et al. Am J Vet Res 40:882, 1979.

INTERPRETATION OF THE FINDINGS & FURTHER RECOMMENDATIONS

Overtly normal cardiac structure and function. The LV wall thickness is normal and there is no evidence of elevated left atrial pressure. No obvious congenital issues are documented. The ECG is unremarkable with a normal sinus rhythm.

These findings would certainly suggest a non-cardiac origin for the prior episodes. This is supported by duration, as most syncopal events last only seconds.



PATIENT

Anzo Alumbaugh

SPECIES

Feline

BREED

Bengal

SEX

Male Intact

AGE

23 weeks

WEIGHT

5.68lbs; 2.6kgs

INTERPRETED BY

Maggie Machen Lamy,
DVM, DACVIM
(Cardiology)

IMAGING PERFORMED BY

Loetitia St-Jacques,
LVT/RVT

HOSPITAL NAME

VCA Feline Animal
Hospital

REFERRING VET

Dr. Fleming

INVOICE

21845

DATE

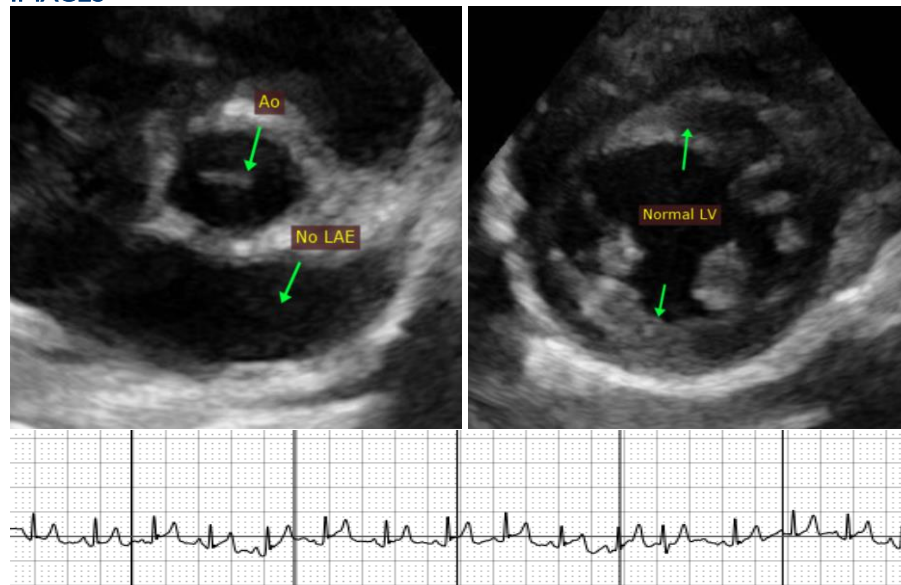
11/2/21

Given these findings, no medications are indicated. It is important to note that phenotypic HCM can develop at any phase of life in cats (particularly in this predisposed breed), and often does not accompany a heart murmur or PE abnormalities. Periodic screening is ideally recommended in all cats.

No cardiac contraindication for breeding or general anesthesia at this time.

Recommend recheck echocardiogram in 1 year to assess for development of disease, sooner if a murmur/gallop or clinical signs develop in the interim.

IMAGES



The information and recommendations provided are based on the images presented by the referring veterinarian. No evaluation can be communicated regarding pathology that was not visible in the image/video clips provided.

Thank you for this referral. This report was generated using transcription software, and minor dictation errors may be present. If the clinical or image interpretation does not parallel your findings or if I can be of any further assistance, please contact me.

Maggie Machen Lamy, DVM
Diplomate of the American College of Veterinary Internal Medicine (Cardiology)
info@sonopath.com